Genetic Basis of Cutaneous Diseases

55



Vered Molho-Pessach and Julie V. Schaffer

Key features

- Advances in molecular technology have led to elucidation of the genetic bases of many single-gene inherited and mosaic skin disorders, greatly improving our understanding of these conditions
- McKusick's Online Mendelian Inheritance in Man (OMIM) database provides easily accessible, up-to-date information on human genes and genetic diseases; each gene or phenotype entry is assigned a specific six-digit MIM number
- Genotype–phenotype correlations in genodermatoses are often complex, with multiple examples of allelic heterogeneity (mutations in a single gene causing more than one disorder) and locus heterogeneity (mutations in different genes causing the same disorder)
- Molecular classification of genodermatoses into categories such as keratin defects and RASopathies complements traditional morphologic classification, highlighting pathomechanisms and relationships between conditions
- Certain syndromic associations actually represent contiguous gene syndromes caused by large deletions that affect two or more neighboring genes
- Types 1 and 2 mosaicism in autosomal dominant disorders have been confirmed on a molecular level, and functional X-chromosome mosaicism can lead to a mosaic distribution of skin lesions in female patients heterozygous for X-linked disorders
- Determining the molecular basis of monogenic skin disorders can enable the development of targeted therapies and provide insights into the pathogenesis of acquired skin diseases
- Molecular research has paved the way to the goal of gene therapy for severe inherited skin disorders such as epidermolysis bullosa

Abbreviations: AD, autosomal dominant; AR, autosomal recessive; XD, X-linked dominant; XR, X-linked recessive.

INTRODUCTION

In 1987, deletions in the steroid sulfatase gene were found to underlie X-linked recessive ichthyosis[1]. This heralded an era of tremendous progress in the elucidation of the genetic bases of inherited skin disorders, made possible by rapid advances in molecular technology (including the development of next-generation massively parallel sequencing; see Fig. 3.5), utilization of animal models, and sequencing of the human genome[2–4]. Better understanding of signaling pathways, molecules involved in cell–cell communication and adhesion, and mechanisms of cutaneous differentiation have also contributed to the momentum.

As a result of this explosion in research, more than 1000 genes were recognized to be responsible for a particular human phenotype by the year 2000, with approximately 300 of these conditions including cutaneous abnormalities[5]; by 2023, these numbers had increased to nearly 5000 and 1700, respectively[6–8]. Currently, the molecular genetic bases of the majority of single-gene inherited skin disorders have been established[9,10]. Multigene panels as well as whole-exome (the transcribed portion of the genome) and whole-genome sequencing utilizing next-generation technology are clinically available to assist in the identification of disease-causing genes[10].

In the past, diagnosis of genodermatoses was complicated by the existence of multiple complex classification systems based on various combinations of clinical, histologic, radiographic, and biochemical criteria. Inconsistent nomenclature laden with descriptive terms, eponyms, and synonyms added to the confusion and potential for misdiagnosis[11]. As the genetic bases of genodermatoses have been determined, integration of molecular and clinical data has helped to simplify disease categorization and eliminate redundant terminology. This has been successfully accomplished for disorders such as epidermolysis bullosa (EB) and ichthyoses, but it represents a work in progress, to be continually refined as additional genotype–phenotype correlations are established[12,13]. In addition, grouping hereditary skin disorders according to their molecular bases (Table 55.1) can supplement traditional morphologic classification, clarifying pathomechanisms and the relationships between conditions. Groups of monogenic conditions listed in tables elsewhere in the book are noted in Table 55.2.

As the "morbid anatomy of the dermatologic genome" continues to be established, new challenges will arise and additional questions will be answered[14]. Because of the rarity of many genodermatoses, their full clinical spectra have yet to be elucidated. However, with the increasing availability of genetic testing, dermatologists can establish the diagnosis in patients with mild or atypical presentations, thereby expanding the range of phenotypes. Continuing to decipher heritable skin disorders will require close interactions between basic scientists and clinicians[15]. Hopefully, such research will continue to lead to better understanding of cutaneous structure and function; insights into the pathogenesis of common multifactorial disorders; and effective therapies as well as diagnostic and prognostic information, improved genetic counseling, and DNA-based prenatal/preimplantation testing for patients with genodermatoses.

McKUSICK'S MENDELIAN INHERITANCE IN MAN

McKusick's Mendelian Inheritance in Man (MIM) database was first published in 1966 as "Catalogs of Autosomal Dominant, Autosomal Recessive and X-linked Phenotypes". In the 1994 edition, the subtitle was changed to "A Catalog of Human Genes and Genetic Disorders", reflecting the progress that had been made in the field. Online MIM (OMIM; https://omim.org/) has been widely available on the Internet for almost 40 years, providing immediate access to current information on human genes and genetic diseases[6,7]. This database is updated continuously and can be searched by entering a constellation of clinical features as well as the name of a gene or syndrome.

A particular six-digit number (MIM number) is assigned to each OMIM entry. The first digit of the MIM number indicates the mode of inheritance of the corresponding genetic defect: 1 for autosomal dominant (entries before May 1994); 2 for autosomal recessive (entries before May 1994); 3 for X-linked; 4 for Y-linked; 5 for mitochondrial; and 6 for autosomal dominant or recessive (entries after May 1994). *Phenotype entries* describe the clinical and biochemical features, inheritance, mapping, and molecular genetics of a given disease or trait; a "#" is used to designate those for which the molecular basis is known (e.g. #162200). *Gene entries* are marked by a "*" (e.g. *613113), while *gene plus phenotype* entries are indicated with a "+" (e.g. +107670); both are appended with important disease-causing allelic variants (each of which is given a four-digit extension, beginning with .0001).

GENOTYPE–PHENOTYPE CORRELATIONS

Genotype–phenotype correlations in genodermatoses are often complex. Mutations in a single gene can cause more than one clinical disorder, a phenomenon referred to as *allelic heterogeneity* (see Table 54.2). This usually results from different mutations in a particular gene. However, it occasionally reflects the same mutation

Downloaded for Anonymous User (n/a) at Egyptian Knowledge Bank from ClinicalKey.com by Elsevier on March 10, 2024. For personal use only. No other uses without permission. Copyright ©2024. Elsevier Inc. All rights reserved.

MOLECULAR CLASSIFICATION OF GENETIC SKIN DISORDERS	
Molecular defect	**Examples of skin disorders that result**
Keratin defects	See Table 56.4 and Fig. 56.5
Defects in structural proteins of the cornified cell envelope	Ichthyosis vulgaris, loricrin keratoderma (variant Vohwinkel syndrome)
Lipid metabolism defects	Various ichthyoses, including CHILD syndrome, Conradi–Hünermann–Happle syndrome, neutral lipid storage disease, lamellar ichthyosis/congenital ichthyosiform erythroderma spectrum (e.g. defective lipoxygenase 3 or 12 R, cytochrome p450 4F22), self-healing collodion baby (defective lipoxygenase 3 or 12 R), late-onset autosomal recessive congenital ichthyosis, Refsum disease, rhizomelic chondrodysplasia punctata, Sjögren–Larsson syndrome, X-linked recessive ichthyosis and ichthyosis, intellectual disability and spastic quadriplegia; various hyperlipidemias; Farber lipogranulomatosis, Gaucher disease type 2, hyperimmunoglobulinemia D syndrome, localized autosomal recessive hypotrichosis II/autosomal recessive woolly hair, Niemann–Pick disease, psoriasiform dermatitis–microcephaly–developmental delay syndrome
Transglutaminase defects	Congenital ichthyosiform erythroderma spectrum (transglutaminase 1), acral peeling skin syndrome
Protease/proteasome defects	Dermatosparaxis, familial hidradenitis suppurativa, hereditary angioedema (type III), Howel–Evans syndrome, ichthyosis–hypotrichosis syndrome, IFAP (*i*chthyosis *f*ollicularis–*a*trichia–*p*hotophobia) syndrome, KLICK (*k*eratosis *l*inearis–*i*chthyosis *c*ongenita–sclerosing *k*eratoderma) syndrome, Olmsted syndrome, Papillon–Lefèvre and Haim–Munk syndromes, prolidase deficiency, restrictive dermopathy (defective zinc metallopeptidase), hereditary thrombotic thrombocytopenic purpura, MONA (*m*ulticentric *o*steolysis, *n*odulosis, and *a*rthropathy), proteasome-associated autoinflammatory/CANDLE/Nakajo–Nishimura syndrome)
Protease inhibitor defects	Antithrombin III deficiency, autosomal recessive exfoliative ichthyosis, hereditary angioedema (types I & II), Netherton syndrome
Desmosomal defects (see Fig. 56.8)	Acantholytic erosive disorder, arrhythmogenic right ventricular dysplasia/cardiomyopathy + palmoplantar keratoderma + woolly hair; Carvajal syndrome, erythrokeratodermia–cardiomyopathy syndrome, generalized inflammatory peeling skin syndrome, hypotrichosis and skin lesions, hypotrichosis simplex of the scalp, localized autosomal recessive hypotrichosis, monilethrix (autosomal recessive), Naxos disease, SAM (severe dermatitis, *a*llergies, and *m*etabolic wasting), skin fragility–ectodermal dysplasia syndrome, skin fragility/woolly hair syndrome, striate palmoplantar keratoderma
Connexin defects (see Table 58.5)	Bart–Pumphrey syndrome, Clouston syndrome, erythrokeratodermia variabilis et progressiva, lymphatic malformation 3, ILVEN, keratoderma–hypotrichosis–leukonychia totalis, KID (*k*eratitis–*i*chthyosis–*d*eafness) syndrome, oculodentodigital dysplasia, palmoplantar keratoderma with deafness, porokeratotic adnexal ostial nevus, Vohwinkel syndrome (classic)
Other defects in cell-to-cell adhesion	Ichthyosis–hypotrichosis–sclerosing cholangitis syndrome, cleft lip/palate–ectodermal dysplasia syndrome, ectodermal dysplasia–syndactyly syndrome, ectodermal dysplasia–ectrodactyly–macular dystrophy, hypotrichosis with juvenile macular dystrophy, leukocyte adhesion deficiency type I
Defects in keratinocyte–extracellular matrix (ECM) adhesion	Various forms of epidermolysis bullosa (EB) simplex, junctional EB, and dystrophic EB (keratin–ECM linkage); Kindler EB (actin–ECM linkage)
ATP-binding cassette (ABC) transporter defects	Harlequin ichthyosis, lamellar ichthyosis/congenital ichthyosiform erythroderma spectrum (defective ABCA12), pseudoxanthoma elasticum, sitosterolemia, Tangier disease/familial hypoalphaproteinemia
Calcium pump defects	Darier disease, Hailey–Hailey disease
Copper transporter defects	Menkes disease, occipital horn syndrome, Wilson disease
Defects in other transporters	Acrodermatitis enteropathica (zinc transporter), arterial tortuosity syndrome (glucose transporter), autosomal dominant hemochromatosis (iron-regulated transporter), spondylodysplastic Ehlers–Danlos syndrome (zinc transporter), H syndrome (nucleoside transporter), Hartnup disease (neutral amino acid transporter), ichthyosis–prematurity syndrome (fatty acid transporter), oculocutaneous albinism (transporters on lysosome-related organelles)
Collagen defects	Various types of dystrophic EB, various types of Ehlers–Danlos syndrome, Ullrich muscular dystrophy, lysyl hydroxylase 3 deficiency
Defects in other ECM proteins	Autosomal dominant cutis laxa, autosomal recessive cutis laxa type I, cutis laxa with severe pulmonary/gastrointestinal/urinary abnormalities, classic-like and hypermobile Ehlers–Danlos syndrome, juvenile hyaline fibromatosis/infantile systemic hyalinosis, lipoid proteinosis, Marfan syndrome, stiff skin syndrome
Nuclear membrane defects (see Table 63.10)	Buschke–Ollendorff syndrome/melorheostosis, Néstor–Guillermo progeria syndrome, Hutchinson–Gilford progeria syndrome, mandibuloacral dysplasia, partial > generalized lipodystrophy (familial and "acquired" forms), restrictive dermopathy
Defects in pyrin/NOD-family members and related proteins (see Fig. 4.2)	Blau syndrome, Yao syndrome, NOMID syndrome, familial cold autoinflammatory syndrome, familial Mediterranean fever, Muckle–Wells syndrome, PAPA syndrome
Interferonopathies (see Ch. 45)	Aicardi–Goutières syndrome, familial chilblain lupus, proteasome-associated autoinflammatory/CANDLE/Nakajo–Nishimura syndrome, SAVI (*S*TING-*a*ssociated *v*asculopathy with onset in *i*nfancy), X-linked reticulate pigmentary disorder
RecQ DNA helicase defects	Bloom syndrome, Rothmund–Thomson syndrome, Werner syndrome
Classic DNA repair defects	Various subtypes of xeroderma pigmentosum, trichothiodystrophy and Cockayne syndrome; Muir–Torre syndrome, constitutional mismatch repair deficiency syndrome
Cell cycle checkpoint defects	Ataxia telangiectasia, familial atypical mole and melanoma (FAMM) syndrome, multiple endocrine neoplasia (MEN) 4
Defects in telomere maintenance	Dyskeratosis congenita (see Table 67.8; 11 genes implicated to date)
RAS–MAPK pathway activation (RASopathies; see Fig. 55.4)	Capillary malformation–arteriovenous malformation, cerebral capillary malformations (familial), cardio-facio-cutaneous syndrome, congenital melanocytic nevi, Costello syndrome, Legius syndrome, neurofibromatosis type 1, Noonan syndrome (with multiple lentigines), Noonan-like disorder with loose anagen hair, verrucous epidermal nevi, nevus sebaceus, woolly hair nevi

Table 55.1 Molecular classification of genetic skin disorders.

Downloaded for Anonymous User (n/a) at Egyptian Knowledge Bank from ClinicalKey.com by Elsevier on March 10, 2024. For personal use only. No other uses without permission. Copyright ©2024. Elsevier Inc. All rights reserved.

MOLECULAR CLASSIFICATION OF GENETIC SKIN DISORDERS	
Molecular defect	**Examples of skin disorders that result**
Phosphatidylinositol 3-kinase (PI3K)/AKT pathway activation	Epidermal nevi, lymphatic malformations, PIK3CA-related overgrowth spectrum (see Table 104.5), Proteus syndrome, PTEN hamartoma tumor syndrome, tuberous sclerosis complex, venous malformations
G protein activation	Diffuse capillary malformation with overgrowth (some patients), extensive dermal melanocytosis, McCune–Albright syndrome (versus loss-of-function in Albright hereditary osteodystrophy), phakomatosis pigmentovascularis, port-wine birthmarks, Sturge–Weber syndrome
cAMP and AMP-activated protein kinase pathway defects (see Fig. 55.3)	Albright hereditary osteodystrophy, Carney complex, McCune–Albright syndrome, Peutz–Jeghers syndrome, tuberous sclerosis complex
Defects in WNT/β-catenin signaling (see Fig. 55.6)	Anonychia congenita, ectodermal dysplasia–neoplastic syndrome, Gardner syndrome, Goltz syndrome (focal dermal hypoplasia), hereditary hypotrichosis simplex, palmoplantar keratoderma with cutaneous SCC and sex reversal, WNT10A-related ectodermal dysplasias (including odonto-onycho-dermal dysplasia and Schöpf–Schulz–Passarge syndrome)
Defects in transforming growth factor (TGF)-β signaling	Buschke–Ollendorff syndrome/melorheostosis, Ferguson–Smith multiple self-healing squamous epitheliomas, hereditary hemorrhagic telangiectasia, Loeys–Dietz syndrome, Marfan syndrome, stiff skin syndrome
Defective vesicle assembly/ protein sorting to vesicles	ARC (*a*rthrogryposis–*r*enal *d*ysfunction–cholestasis) syndrome, Hermansky–Pudlak syndrome, MEDNIK (*m*ental disability, *e*nteropathy, *d*eafness, *n*europathy, *i*chthyosis, *k*eratodermia) syndrome
Defective vesicle trafficking or transport	Autosomal recessive cutis laxa type IIA, CEDNIK (*c*erebral *d*ysgenesis, *n*europathy, *i*chthyosis and *k*eratoderma) syndrome, Chédiak–Higashi syndrome, gerodermia osteodysplastica, Griscelli syndrome, ocular albinism type 1, wrinkly skin syndrome, MACS (*m*acrocephaly, *a*lopecia, *c*utis laxa and *s*coliosis) syndrome

Table 55.1 Molecular classification of genetic skin disorders. cAMP, cyclic adenosine monophosphate; CANDLE, chronic atypical neutrophilic dermatosis with lipodystrophy and elevated temperature; CHILD, congenital hemidysplasia with ichthyosiform nevus and limb defects; JAK, Janus kinase; MAPK, mitogen-activated protein kinase; NF-κB, nuclear factor-κB; NOD, nucleotide-binding oligomerization domain; NOMID, neonatal-onset multisystem inflammatory disease; PAPA, pyogenic arthritis, pyoderma gangrenosum, and acne; SCC, squamous cell carcinoma; STAT, signal transduction and activation of transcription; STING, stimulator of interferon genes; WNT, wingless-type integration site.

in patients with different ages at presentation, e.g. Cowden syndrome and Bannayan–Riley–Ruvalcaba syndrome (*PTEN*), or the same *mosaic* mutation affecting different cell types, e.g. nevus spilus and nevus sebaceus (*HRAS*). Mutations that affect different domains of a protein can produce divergent phenotypes; for example, mutations in the sterile alpha motif (SAM) domain of the p63 protein typically cause AEC (*a*nkyloblepharon, *e*ctodermal dysplasia, and *c*left lip/palate) syndrome, while those in the DNA-binding domain give rise to EEC (*e*ctrodactyly, *e*ctodermal dysplasia, and *c*left lip/palate) syndrome. Different mutations in a gene can also lead to disorders with distinct modes of inheritance, such as X-linked dominant incontinentia pigmenti and X-linked recessive hypohidrotic ectodermal dysplasia with immunodeficiency due to a partial deletion and milder, "hypomorphic" mutations in *IKBKG* (inhibitor of nuclear factor κB kinase regulatory subunit γ; *NEMO*), respectively. Lastly, mutations with opposite effects on a gene can produce disorders with completely disparate phenotypes, such as Ferguson–Smith multiple self-healing squamous epithelioma and Loeys–Dietz syndrome due to loss-of-function versus gain-of-function mutations in *TGFBR1* (TGF-β receptor 1), respectively.

The type of mutation can also affect the severity of a genodermatosis. The oftentimes lethal severe form of junctional EB (JEB), an *autosomal recessive* disorder, is typically caused by *LAMB3* mutations that produce a premature termination codon and absence of the LAMB3 protein. In contrast, milder forms of JEB result from missense mutations that result in decreased LAMB3 function. Conversely, in *autosomal dominant* conditions such as piebaldism (*KIT*) where the mutated protein forms a dimer, *dominant negative* missense mutations often result in more severe disease (via abnormal proteins disrupting normal proteins) than do premature termination codons that produce *haploinsufficiency* (absence of half of the proteins).

In other instances, mutations in different genes produce the same clinical disorder. This *locus heterogeneity* typically occurs when the mutated proteins serve a similar function. Examples include proteins interacting: (1) in a *complex*, e.g. components of various BLOCs (*b*iogenesis of *l*ysosome-related *o*rganelle *c*omplexes) in Hermansky–Pudlak syndrome (see Fig. 65.8A); (2) as a *ligand and receptor*, e.g. endothelin-3 and the endothelin-B receptor in type 4 Waardenburg syndrome (see Fig. 65.3); or (3) in a *signaling pathway*, e.g. RAS/mitogen-activated protein kinase [MAPK] pathway proteins in cardio-facio-cutaneous syndrome (see below). However, some phenotypic differences can arise when these proteins also have distinct functions and/or tissue distributions. For example, the neurologic abnormalities in Griscelli syndrome 1 result from myosin Va expression in neurons, and the immunodeficiency and hemophagocytic syndrome that characterize Griscelli syndrome 2 reflect RAB27A expression in hematopoietic cells.

MOLECULAR CLASSIFICATION OF HEREDITARY SKIN DISORDERS

Molecular classification (see Table 55.1) represents a useful approach to the categorization of genodermatoses. Based on the pathogenetic defect rather than the clinical presentation, it can facilitate better understanding of important cellular pathways such as phosphatidylinositol 3-kinase (PI3K)/AKT or RAS/MAPK signaling (see Fig. 113.1). Several groups of genodermatoses for which molecular classification has been instructive are discussed below.

Keratin Defects

In 1991, EB simplex became the first human disease shown to be caused by intermediate filament mutations. Molecular defects in keratins have subsequently been identified in a diverse group of hereditary skin disorders, with manifestations including mechanical fragility (EB simplex), scaling/hyperkeratosis (keratinopathic ichthyoses, palmoplantar keratodermas [PPKs]), hyperpigmentation (Dowling–Degos disease), nail dystrophy (pachyonychia congenita), hair abnormalities (monilethrix), oral mucosal changes (white sponge nevus), and ectodermal dysplasia (Naegeli–Franceschetti–Jadassohn syndrome) (see Table 56.4)[16].

Keratin intermediate filaments are expressed in a tissue- and differentiation-specific fashion. They are composed of heterodimeric subunits formed by the specific pairing of a type I (acidic) and type II (basic–neutral) keratin (see Ch. 56). Many keratin disorders can be caused by mutations (often dominant negative) in either the type I or type II component of a particular keratin pair, thus exhibiting locus heterogeneity (e.g. KRT10 or KRT1 for epidermolytic ichthyosis; KRT14 or KRT5 for EB simplex). Allelic heterogeneity is also observed, with mutations in the highly conserved helix initiation and termination motifs leading to more severe phenotypes (e.g. severe EBS) than those in other regions (e.g. localized EBS) (see Fig. 56.5).

Downloaded for Anonymous User (n/a) at Egyptian Knowledge Bank from ClinicalKey.com by Elsevier on March 10, 2024. For personal use only. No other uses without permission. Copyright ©2024. Elsevier Inc. All rights reserved.

GROUPS OF MONOGENIC SKIN DISORDERS LISTED IN TABLES ELSEWHERE IN THE BOOK	
Category	**Table(s)**
Congenital insensitivity to pain and related neuropathies	Table 6.10
Epidermolysis bullosa and other blistering disorders	Tables 32.1 & 32.3
Sclerodermoid disorders	Table 43.7
Autoinflammatory diseases	Tables 45.2 & 45.7
Porphyrias	Table 49.3
Keratinopathies and desmosomal disorders	Table 56.4; Figs. 56.5 & 56.8
Ichthyoses	Tables 57.1, 57.2, 57.6, 57.7 & 57.8
Connexin disorders and keratodermas	Tables 58.5 & 58.6
Primary immunodeficiencies	Tables 60.4, 60.6, 60.8, 60.10, 60.13, 60.15 & 60.16
Disorders associated with multiple café-au-lait macules	Table 61.3
Epidermal nevi and other mosaic disorders	Tables 62.3 & 62.6
Progeroid syndromes/inherited poikilodermas and nuclear membrane disorders	Tables 63.9 & 63.10
Ectodermal dysplasias	Tables 63.11–63.13
Aplasia cutis congenita, cleft lip/palate, and digital anomalies	Tables 64.3–64.6
Disorders of hypopigmentation (diffuse or circumscribed)	Tables 65.1 & 66.4
Disorders with reticulated hyperpigmentation, dyskeratosis congenita, and dyschromatoses	Tables 67.8, 67.9 & 67.11
Hypotrichosis, hair shaft disorders, and hypertrichosis	Tables 69.7; 70.1 & 70.2
Xeroderma pigmentosa and other photosensitivity disorders	Table 87.4
Hyperlipidemias	Table 92.2
Ehlers–Danlos syndrome, cutis laxa, and other extracellular matrix disorders	Tables 95.5; 97.1, 97.2 & 97.7
Lipodystrophy syndromes	Table 101.1
Vascular anomalies and overgrowth syndromes	Tables 104.2 & 104.5
Lymphatic malformations/lymphedema	Table 105.7
Disorders with multiple lentigines	Table 112.2

Table 55.2 Groups of monogenic skin disorders listed in tables elsewhere in the book. In addition, other chapters (especially in the genodermatosis section) have tables that present more detailed information on monogenic skin disorders.

Defects in Intercellular Junctions

Mutations in genes encoding components of desmosomes and gap junctions underlie a variety of genodermatoses, several of which have prominent extracutaneous manifestations.

Desmosomal defects

Desmosomes are intercellular junctions that provide mechanical integrity to tissues by anchoring intermediate filaments to the cell surface and mediating strong cell–cell adhesion (see Fig. 29.3B). They are particularly important in stratified squamous epithelia and the myocardium, tissues that are subjected to substantial mechanical stress[17]. It is therefore not surprising that impaired keratinization (especially PPK), skin fragility, and cardiomyopathy represent features of disorders caused by defects in desmosomal proteins such as desmoplakin, plakoglobin, and plakophilin 1 (see Fig. 56.8). Abnormal hair (oftentimes woolly in nature) can also result from abnormalities in these proteins, and defects in other desmosomal components such as desmoglein 4 and corneodesmosin (which are highly expressed within the hair follicle) can lead to hypotrichosis and (for desmoglein 4) an autosomal recessive form of monilethrix (Fig. 55.1). Additional consequences of desmosomal defects include inflammatory peeling skin (corneodesmosin) and *s*evere dermatitis, *a*llergies, and *m*etabolic wasting (SAM; desmoglein 1, desmoplakin).

Fig. 55.1 Autosomal recessive monilethrix due to desmoglein 4 mutations. Sparse short hairs, stubble, and follicular papules on the scalp. Inset: Trichogram showing alternating elliptical nodes and constrictions.

Connexin defects

Gap junctions are intercellular channels that connect the cytoplasm of neighboring cells, facilitating communication that coordinates cellular growth, differentiation and responses to stimuli as well as tissue morphogenesis and homeostasis (see Ch. 58). Transmembrane connexin proteins undergo oligomerization to form the connexons that compose gap junctions. Connexin proteins such as Cx26, Cx30, Cx31, and Cx43 are preferentially expressed in ectoderm-derived epithelia of the inner ear and cornea as well as in the epidermis and its appendages[18]. This accounts for the sensorineural deafness, keratitis, and cutaneous abnormalities ranging from keratoderma to erythrokeratoderma to ectodermal dysplasias affecting the hair and nails that are observed in various connexin disorders (see Table 55.1). Several connexins are expressed in lymphatic cells, and mutations in the gene encoding Cx47 (*GJC2*) cause a hereditary type of lymphedema[19].

Defects in Keratinocyte–Extracellular Matrix Adhesion

The hemidesmosome links keratin intermediate filaments (KRT5, KRT14) within basal keratinocytes to proteins within the lamina densa (basement membrane proper) and sublamina densa regions of the epidermal basement membrane zone (see Ch. 28). Defects in protein components of these structures lead to various forms of EB (simplex, junctional, and dystrophic; see Ch. 32)[20]. The basement membranes of epithelia in other sites such as the eye, oral cavity, gastrointestinal tract, and genitourinary tract may also be affected in patients with EB. Additional clinical manifestations can result when the abnormal protein has important functions in extraepithelial tissues, such as the skeletal muscle for plectin (leading to EBS with muscular dystrophy).

Focal adhesions are structurally defined sites of linkage between the intracellular actin cytoskeleton and the extracellular matrix (ECM; see

Downloaded for Anonymous User (n/a) at Egyptian Knowledge Bank from ClinicalKey.com by Elsevier on March 10, 2024. For personal use only. No other uses without permission. Copyright ©2024. Elsevier Inc. All rights reserved.

Fig. 28.3B). Mutations in the gene encoding the focal adhesion protein kindlin-1 cause Kindler EB, an autosomal recessive disorder characterized by acral blistering and photosensitivity early in life, progressive poikiloderma, and erosive periodontal disease (see Ch. 32). Kindlin-1 is found within basal keratinocytes along the cell surface that faces the basement membrane, and it has roles in keratinocyte adhesion, polarity, proliferation, and motility. To date, Kindler EB represents the only skin fragility disorder known to be caused by disruption of linkage between actin microfilaments (rather than keratin intermediate filaments) and the ECM[20].

Transmembrane Transporter Defects

Abnormalities in transmembrane transporters underlie a variety of genodermatoses, ranging from oculocutaneous albinism due to defective transporters on lysosome-related organelles to metabolic disorders such as acrodermatitis enteropathica. This list also includes defects in a fatty acid transporter in ichthyosis prematurity syndrome[21] and an intracellular nucleoside transporter in H syndrome (Fig. 55.2)[22]. Disorders of calcium pumps and ATP-binding cassette (ABC) transporters, which underscore the important roles of transmembrane transporters in cutaneous homeostasis, are discussed below.

Calcium pump defects

Darier disease and Hailey–Hailey disease are distinct autosomal dominant disorders that share the histologic feature of epidermal acantholysis leading to suprabasal cleft formation; on an ultrastructural level, this corresponds to disruption of the desmosome–keratin intermediate filament complex. The two conditions also have some clinical similarities, including intertriginous involvement, vesiculobullous lesions (relatively uncommon in Darier disease), nail changes, exacerbation with heat, and frequent superinfections. As a result of these overlapping features, it was initially postulated that Darier disease and Hailey–Hailey disease were allelic disorders caused by defects in a gene encoding a structural component of the epidermis. In 1999, pathogenetic mutations in *ATP2A2*, which encodes a sarcoplasmic/endoplasmic reticulum Ca^{2+} ATPase, were identified in patients with Darier disease. Subsequently, mutations in *ATP2C1*, which encodes a Ca^{2+} ATPase localized to the Golgi apparatus, were shown to cause Hailey–Hailey disease (see Fig. 59.1). Determining the molecular bases of these genodermatoses thus demonstrated the pivotal role of calcium homeostasis in epidermal differentiation and cell–cell adhesion[23].

Fig. 55.2 H syndrome (histiocytosis-lymphadenopathy plus syndrome). This autosomal recessive disorder due to mutations in the *SLC29A3* gene (which encodes a nucleoside transporter) presents with *h*yperpigmentation, *h*ypertrichosis, induration, and varicose veins in a characteristic distribution pattern on the thighs with sparing of the knees (**A**). Additional features include *h*allux valgus and flexion contractures of the toes (**B**), *h*epatosplenomegaly, *h*eart anomalies, *h*earing loss, *h*ypogonadism, low *h*eight and *h*yperglycemia/diabetes mellitus.

ATP-binding cassette transporter defects

Members of the ABC transporter superfamily bind and hydrolyze adenosine triphosphate (ATP) in order to transport various molecules across a cell membrane or into a vesicle. Well-known examples include the CFTR (cystic fibrosis transmembrane conductance regulator) chloride ion channel that is defective in patients with cystic fibrosis and the P glycoprotein that mediates multidrug resistance. Several phenotypically diverse genodermatoses are also caused by mutations in ABC transporters (see Table 55.1)[24].

Because pseudoxanthoma elasticum (PXE) features fragmentation and calcification of elastic fibers, this autosomal recessive disorder was initially postulated to result from mutations in an extracellular matrix protein with roles in the skin, eyes, and cardiovascular system. Surprisingly, PXE was instead found to be caused by mutations in *ABCC6*, which encodes a hepatocyte efflux pump that transports ATP to the extracellular space. Extracellular ATP is rapidly converted to AMP and inorganic pyrophosphate (PPi), with the latter representing a physiologic anti-mineralization factor. PXE therefore actually represents a metabolic disorder with secondary connective tissue manifestations.

Biallelic mutations in *ABCA12*, which encodes a transporter that secretes lipids into lamellar granules, cause both harlequin ichthyosis and a form of lamellar ichthyosis[25] (see Fig. 56.2). Patients with harlequin ichthyosis tend to have nonsense mutations, whereas those with lamellar ichthyosis typically have missense mutations. This represents one of the most clearcut genotype–phenotype correlations observed to date for nonsyndromic autosomal recessive ichthyoses. Defective formation of intercellular lipid layers, which are essential for epidermal barrier function, due to genetic defects in lipid metabolism also represents the pathomechanism of an expanding list of other ichthyosiform disorders (see Table 55.1 and Fig. 56.2)[25].

Nuclear Envelope Defects

"Nuclear envelopathies" represent a clinically heterogeneous group of inherited disorders caused by defects in structural components of the nuclear envelope (see Table 63.10). In addition to a variety of extracutaneous findings – e.g. skeletal dysplasia, muscular dystrophy, cardiomyopathy, and neuropathy – dermatologic manifestations include: premature aging of the skin, e.g. in progeria and "atypical Werner syndrome" due to *LMNA* mutations; cutaneous fibrosis, e.g. in restrictive dermopathy and Buschke–Ollendorff syndrome/melorheostosis due to *LMNA* and *LEMD3* mutations, respectively; and partial lipodystrophy, e.g. familial Dunnigan and "acquired" Barraquer–Simons types due to *LMNA* and *LMNB2* mutations, respectively.

"Laminopathies" represent the largest subgroup of envelopathies and result from mutations in the genes that encode the lamin A/C and lamin B2 proteins of the nuclear membrane lamina, which lies just inside the inner nuclear membrane[26]. *LEMD3* encodes MAN1, an inner nuclear membrane protein that associates with lamin A. In addition to "true" envelopathies, mutations in *ZMPSTE24*, which encodes a zinc metallopeptidase involved in the processing of prelamin A into mature lamin A, can result in restrictive dermopathy and mandibuloacral dysplasia characterized by lipodystrophy, premature aging, and skeletal defects. The study of patients with envelopathies has provided insight into the importance of lamins and other nuclear envelope proteins to the structural integrity of the nucleus, chromatin organization, transcriptional regulation, control of differentiation, and mechanisms of aging[26].

Downloaded for Anonymous User (n/a) at Egyptian Knowledge Bank from ClinicalKey.com by Elsevier on March 10, 2024. For personal use only. No other uses without permission. Copyright ©2024. Elsevier Inc. All rights reserved.

Defects in Pyrin/NOD Family Members and Related Proteins

The molecular bases of several hereditary periodic fever syndromes and other autoinflammatory disorders have been found to be due to defects in proteins containing *n*ucleotide-binding *o*ligomerization *d*omains (NODs) and/or pyrin domains (see Table 45.2)[27]. This has drawn attention to the NOD and pyrin families and related proteins (see Fig. 4.2), helping to uncover their importance in innate immune responses and acquired inflammatory disorders. Defects in such proteins lead to diverse cutaneous phenotypes, ranging from urticarial papules in cryopyrin-related disorders and erysipeloid erythema in familial Mediterranean fever to nodulocystic acne and pyoderma gangrenosum in PAPA syndrome to granulomatous dermatitis (together with arthritis and uveitis) in Blau syndrome (see Fig. 45.11C). Upon uncovering *NOD2* mutations as the defect in Blau syndrome, it was also established that this autosomal dominant disorder and sporadic "early-onset sarcoidosis" are identical on a genetic as well as phenotypic level (with the latter resulting from *de novo NOD2* mutations), thus representing a single disease entity. However, other *NOD2* variants have been implicated in Crohn disease and susceptibility to leprosy.

Defects in DNA Repair Genes, Tumor Suppressor Genes, and Oncogenes

Hereditary tumor syndromes that affect the skin can be divided into groups based upon whether the associated neoplasms are primarily benign skin tumors (Table 55.3), skin cancers (Table 55.4), or extracutaneous malignancies (Table 55.5); individuals in the latter group may have either benign cutaneous neoplasms (e.g. Cowden syndrome) or non-neoplastic skin lesions (e.g. ataxia–telangiectasia)[28]. To complement this clinical approach, molecular classification of such syndromes can help to explain relationships among disorders, understand the

SELECTED HEREDITARY DISORDERS CHARACTERIZED BY BENIGN SKIN TUMORS			
Disorder	**Mode of inheritance**	**Gene or gene product**	**Gene symbol**
Familial cylindromatosis; Brooke–Spiegler syndrome; multiple familial trichoepitheliomas	AD	CYLD (deubiquitinating enzyme)	*CYLD*
Familial mastocytosis ± gastrointestinal stromal tumors*	AD	KIT proto-oncogene (stem cell factor receptor)	*KIT*
Lipomatosis, familial multiple	AD		
Lipomatosis, benign symmetric (Madelung disease)†	mt	Mitochondrial tRNA-lysine	*MT-TK*
	AR	Mitofusin 2	*MFN2*
	AR	Lipase E, hormone sensitive	*LIPE*
Ferguson–Smith multiple self-healing squamous epitheliomas	AD	Transforming growth factor-β receptor 1 (loss-of-function mutations)	*TGFBR1*
Neurofibromatosis type 1‡	AD	Neurofibromin 1 (GTPase activating protein)	*NF1*
Neurofibromatosis type 2	AD	Neurofibromin 2 (merlin)	*NF2*
Tuberous sclerosis complex	AD	Hamartin	*TSC1*
	AD	Tuberin	*TSC2*

*Occasionally malignant.
†Associated with myoclonic epilepsy with ragged red fibers (MT-TK mutations), neuropathy (MFN2 mutations), or partial lipodystrophy and myopathy (LIPE mutations).
‡Also associated with malignant peripheral nerve sheath tumors.

Table 55.3 Selected hereditary skin disorders characterized by benign skin tumors. Disorders associated with extracutaneous cancer as well as benign skin tumors are listed in Table 55.5. These conditions are discussed in Chapters 61, 62, 104, 117, and 118. mt, mitochondrial inheritance.

SELECTED HEREDITARY DISORDERS ASSOCIATED WITH SKIN CANCER			
Disorder	**Mode of inheritance**	**Gene or gene product**	**Gene symbol**
Bazex–Dupré–Christol syndrome	XD	Actin-related protein T1	*ACTRT1*
Epidermodysplasia verruciformis	AR	Transmembrane channel-like 6	*TMC6*
	AR	Transmembrane channel-like 8	*TMC8*
BAP1 tumor predisposition syndrome*	AD	BRCA-associated protein 1	*BAP1*
Familial atypical mole and melanoma (FAMM) syndrome*	AD	Cyclin-dependent kinase inhibitor 2A†	*CDKN2A*
	AD	Cyclin-dependent kinase 4	*CDK4*
Basal cell nevus syndrome	AD	Patched 1	*PTCH1*
	AD	Patched 2	*PTCH2*
	AD	Suppressor of fused homolog (Drosophila)	*SUFU*
Huriez syndrome (sclerotylosis)	AD		
Palmoplantar keratoderma with cutaneous SCC and sex reversal	AR	R-spondin 1	*RSPO1*
Pigmentation defects, palmoplantar keratoderma, and cutaneous SCC	AR	SAM and SH3 domain-containing 1	*SASH1*
Xeroderma pigmentosum (see Table 87.4)			

*Also associated with melanocytic nevi.
†Also associated with increased risk of developing pancreatic cancer.

Table 55.4 Selected hereditary disorders associated with skin cancer. These conditions are discussed in Chapters 79, 87, 99, 108, and 112. SCC, squamous cell carcinoma.

Downloaded for Anonymous User (n/a) at Egyptian Knowledge Bank from ClinicalKey.com by Elsevier on March 10, 2024. For personal use only. No other uses without permission. Copyright ©2024. Elsevier Inc. All rights reserved.

SELECTED HEREDITARY SKIN DISORDERS ASSOCIATED WITH EXTRACUTANEOUS CANCER				
Disorder	**Mode of inheritance**		**Gene or gene product**	**Gene symbol**
Ataxia–telangiectasia	AR		Ataxia–telangiectasia mutated (phosphatidylinositol 3-kinase-like serine/threonine protein kinase)	*ATM*
Birt–Hogg–Dubé syndrome	AD		Folliculin	*FLCN*
Bloom syndrome	AR		RecQ protein-like 3 (DNA helicase)	*BLM (RECQL3)*
Costello syndrome (see text)	AD		v-Ha-ras Harvey rat sarcoma viral oncogene homolog	*HRAS*
	AD		v-Ki-ras2 Kirsten rat sarcoma viral oncogene homolog	*KRAS*
Dyskeratosis congenita (see Table 67.9)				
Ectodermal dysplasia–neoplastic syndrome	AD		Axis inhibitor 2	*AXIN2*
Gardner syndrome (variant of familial adenomatous polyposis)	AD		Adenomatous polyposis coli	*APC*
Howel–Evans syndrome (tylosis–esophageal carcinoma)	AD		Rhomboid 5 homolog 2	*RHBDF2*
Leiomyomatosis, cutaneous and uterine (Reed syndrome)	AD		Fumarate hydratase	*FH*
Muir–Torre syndrome (variant of Lynch syndrome)	AD		MutS homolog 2 (mismatch repair enzyme)	*MSH2*
	AD		MutS homolog 6 (mismatch repair enzyme)	*MSH6*
	AD		MutL homolog 1 (mismatch repair enzyme)	*MLH1*
MUTYH-associated polyposis	AR		MutY homolog	*MUTYH*
Constitutional mismatch repair deficiency syndrome (childhood tumor syndrome with neurofibromatosis type 1 phenotype)	AR		MutS homolog 2 (mismatch repair enzyme)	*MSH2*
	AR		MutS homolog 6 (mismatch repair enzyme)	*MSH6*
	AR		MutL homolog 1 (mismatch repair enzyme)	*MLH1*
	AR		Postmeiotic segregation increased 2 (mismatch repair enzyme)	*PMS2*
Multiple endocrine neoplasia (MEN)	MEN 1	AD	Menin	*MEN1*
	MEN 2A	AD	Ret proto-oncogene (cysteine-rich extracellular domain)	*RET*
	MEN 2B	AD	Ret proto-oncogene (particularly Met918Thr in substrate recognition pocket)	*RET*
	MEN 4	AD	Cyclin-dependent kinase inhibitor 1B (p27, Kip1)	*CDKN1B*
PTEN hamartoma tumor syndrome (including Cowden and Bannayan–Riley–Ruvalcaba syndromes)	AD		Phosphatase and tensin homolog	*PTEN*
Rothmund–Thomson syndrome	AR		RecQ protein-like 4 (DNA helicase)	*RECQ4*

Table 55.5 Selected hereditary skin disorders associated with extracutaneous cancer. These conditions are discussed in Chapters 60, 63, 67, 87, and 117.

disrupted pathway or process, and suggest candidate genes for patients with similar phenotypes for which the underlying molecular defect has not yet been identified. In addition to characterization based on the specific pathomechanism (e.g. RAS–MAPK pathway activation[29]; see below), hereditary cancer syndromes can be separated into three general categories: (1) defective DNA repair and protection of genomic integrity ("caretaker" genes); (2) defective tumor suppressor ("gatekeeper") genes; and (3) activated oncogenes.

Defective DNA repair and protection of genomic integrity

Inactivation of caretaker genes causes an increased mutation rate in all genes, including gatekeeper genes with critical roles in controlling tumor growth (see below). Classic examples of caretaker dysfunction include defects in the nucleotide excision repair of UV-induced DNA damage in xeroderma pigmentosum and abnormal mismatch repair in the Muir–Torre syndrome subtype of the hereditary non-polyposis colorectal cancer syndrome. Defects in RecQ helicases, which function in DNA replication, recombination, and repair, underlie Bloom, Rothmund–Thomson, and Werner syndromes. This leads to genomic instability, as evidenced by findings such as accumulation of chromosomal aberrations, increased sister chromatid exchange (Bloom syndrome), and shortened telomeres (Werner syndrome). The compromised telomere maintenance observed in dyskeratosis congenita can result from defects in telomerase subunits (RNA and reverse transcriptase) or associated proteins (e.g. dyskerin, a Cajal body protein, ribonucleoprotein homologs, shelterin complex components; see Table 67.9).

Defective tumor suppressor genes

In hereditary cancer syndromes caused by a defective tumor suppressor gene, there is classically a heterozygous germline loss-of-function mutation followed by a somatic "second hit" that leads to loss of heterozygosity and abrogation of protein function in affected tissues. Examples include *PTCH* (encoding patched) in basal cell nevus syndrome, *CDKN2A* (encoding $p16^{INK4a}$ and $p14^{ARF}$, which maintain activity of the retinoblastoma [Rb] and p53 tumor suppressor proteins, respectively) in the familial atypical mole and melanoma syndrome (see Fig. 107.4), and *PTEN* in the PTEN hamartoma tumor syndrome (see Table 63.3). The PTEN protein negatively regulates the PI3K/AKT cascade, which is positively regulated by the RET oncogene (Fig. 55.3; see below). The *PIK3CA*-related overgrowth spectrum and Proteus syndrome are caused by mosaicism for an activating mutation in *PIK3CA* and *AKT1* oncogenes, respectively. The roles of these proteins in the same pathway explains these conditions' clinical similarity to one another as well as to mosaic forms of PTEN hamartoma tumor syndrome (see Table 104.5 and below).

Activated oncogenes

Germline *gain*-of-function mutations in oncogenes have been identified in some autosomal dominant hereditary tumor syndromes, including *RET* in multiple endocrine neoplasia (MEN) 2A/2B (see Fig. 55.3), *KIT* in familial mastocytosis plus gastrointestinal stromal tumors, and those encoding RAS–MAPK pathway components in some "RASopathies" (Fig. 55.4). The latter include Costello (Fig. 55.5), Noonan, and

Downloaded for Anonymous User (n/a) at Egyptian Knowledge Bank from ClinicalKey.com by Elsevier on March 10, 2024. For personal use only. No other uses without permission. Copyright ©2024. Elsevier Inc. All rights reserved.

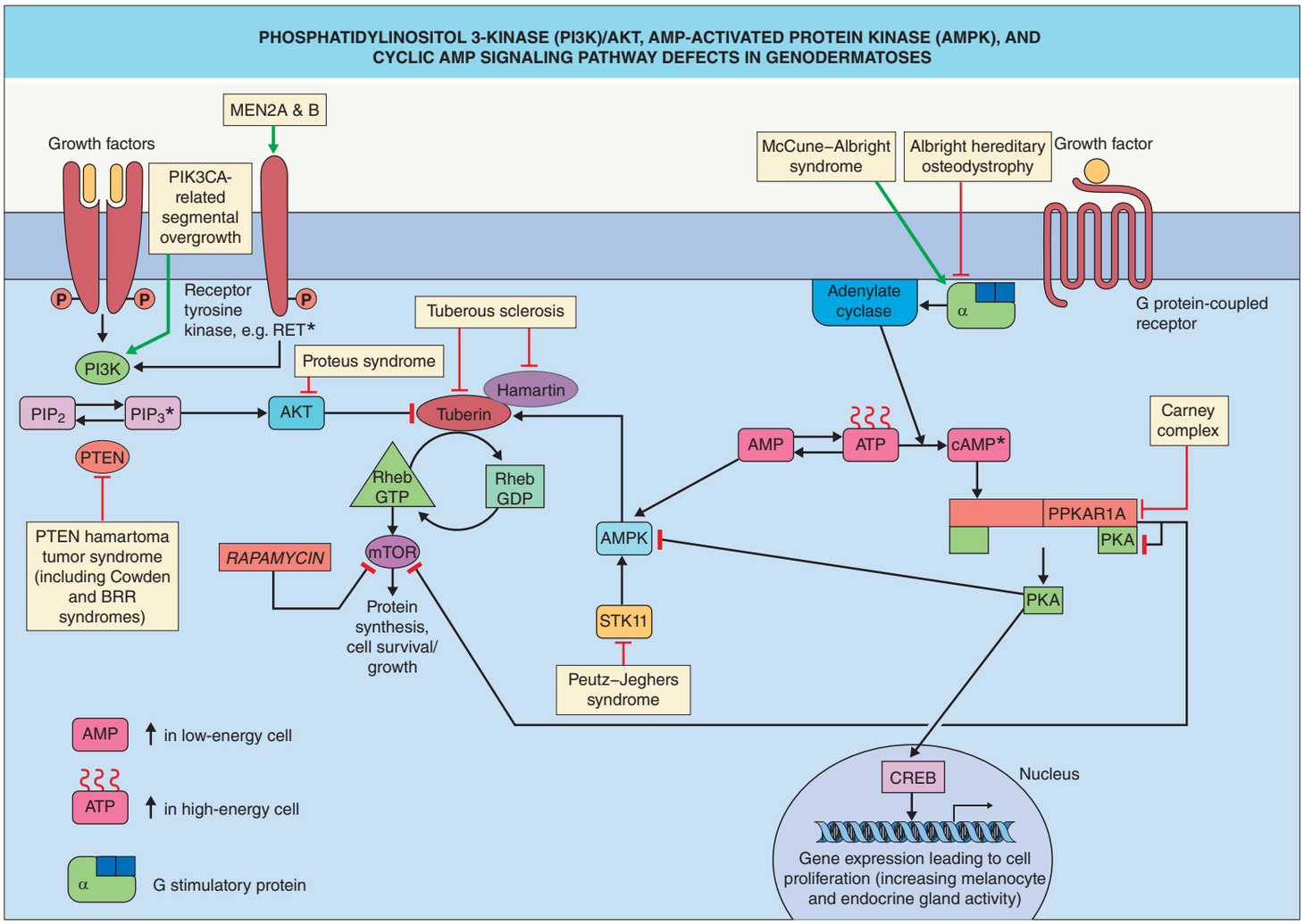

Fig. 55.3 Phosphatidylinositol 3-kinase (PI3K)/AKT, AMP-activated protein kinase (AMPK), and cyclic AMP signaling pathway defects in genodermatoses. The PI3K/AKT pathway is negatively regulated by the PTEN tumor suppressor protein and can be stimulated by a variety of receptor tyrosine kinases as well as by RAS (via cross-talk with the RAS–ERK pathway; see Fig. 55.4). AKT (protein kinase B) inhibits the GTPase activating-protein tuberin, which leads to increased *m*ammalian *t*arget *o*f *r*apamycin (mTOR) activity and resultant cell growth. During periods of nutrient depletion (high AMP/low ATP), serine–threonine kinase 11 (STK11) promotes AMPK-mediated activation of tuberin, which results in decreased mTOR activity and less protein synthesis. Ligand binding to G protein-coupled receptors activates adenylate cyclase, producing increased intracellular cAMP and activation of protein kinase A catalytic subunits (PKA; via release from *p*rotein *k*inase *A* *r*egulatory subunit 1α [PRKAR1A]); this leads to transcription of *c*AMP *r*esponse *e*lement *b*inding protein (CREB)-controlled genes as well as inhibition of AMPK (which is also negatively regulated by AKT). *Other effector pathways include activation of RAS–ERK (see Fig. 55.4). AMP, adenosine monophosphate; ATP, adenosine triphosphate; BRR, Bannayan–Riley–Ruvalcaba; ERK, *e*xtracellular signal-*r*egulated *k*inase; GDP, guanosine diphosphate; GTP, guanosine triphosphate; PIP_2, phosphatidylinositol diphosphate; PIP_3, phosphatidylinositol triphosphate; PTEN, phosphatase and tensin homolog deleted on chromosome 10.

cardio-facio-cutaneous (CFC) syndromes as well as Noonan with multiple lentigines (LEOPARD) syndrome[29,30]. In addition, neurofibromatosis type 1 (NF1), Legius syndrome (previously referred to as NF1-like syndrome), and capillary malformation–arteriovenous malformation (CM-AVM) represent RASopathies due to germline *loss*-of-function mutations in tumor suppressor genes that normally downregulate RAS–MAPK signaling[29].

RASopathies share extracutaneous features such as ocular hypertelorism, macrocephaly, cardiac defects (especially pulmonary stenosis), and developmental delay, as well as a spectrum of skin findings that includes hair abnormalities (e.g. curly, woolly, loose anagen), pigmented lesions (e.g. lentigines, melanocytic nevi, café-au-lait macules)[31], keratosis pilaris, acanthosis nigricans, and distal phalangeal transverse creases (see Fig. 55.5B&C). Some RASopathies also have more specific cutaneous manifestations, such as neurofibromas in NF1, lax acral skin in Costello syndrome (see Fig. 55.5B), and capillary and arteriovenous malformations in CM-AVM. Different RASopathies are associated with variably increased risks for the development of benign (e.g. neurofibromas in NF1) and malignant (e.g. rhabdomyosarcoma in Costello syndrome) tumors. Targeted drugs aimed at proteins in the RAS–MAPK pathway hold promise for the treatment of sporadic cancers (e.g. BRAF inhibitors for melanoma) as well as RASopathies themselves (e.g. MEK inhibitors for plexiform neurofibromas)[32].

Defects in WNT/β-Catenin Signaling

WNT (*w*ingless-type *int*egration site) family members are lipid-modified, secreted signaling proteins that play important roles in numerous physiologic and pathologic processes, ranging from stem cell differentiation, cell polarity/adhesion, and tissue morphogenesis/maintenance (including hair follicle development) to wound repair, inflammation, oncogenesis, and aging. WNT signaling can be divided into canonical (β-catenin-dependent) and non-canonical (β-catenin-independent) pathways. Several genodermatoses result from defects in proteins that function in the WNT/β-catenin pathway (Fig. 55.6). Goltz syndrome (focal dermal hypoplasia; Fig. 55.7) is caused by mutations in *PORCN*, which encodes an O-acyltransferase in the endoplasmic reticulum that palmitoylates and thereby facilitates secretion of WNT proteins. Mutations in *WNT10A* produce several relatively common forms of ectodermal dysplasia as well as Schöpf–Schulz–Passarge syndrome (featuring hidrocystomas and palmoplantar keratoderma with eccrine syringofibroadenomatosis). Gardner syndrome (a variant

Downloaded for Anonymous User (n/a) at Egyptian Knowledge Bank from ClinicalKey.com by Elsevier on March 10, 2024. For personal use only. No other uses without permission. Copyright ©2024. Elsevier Inc. All rights reserved.

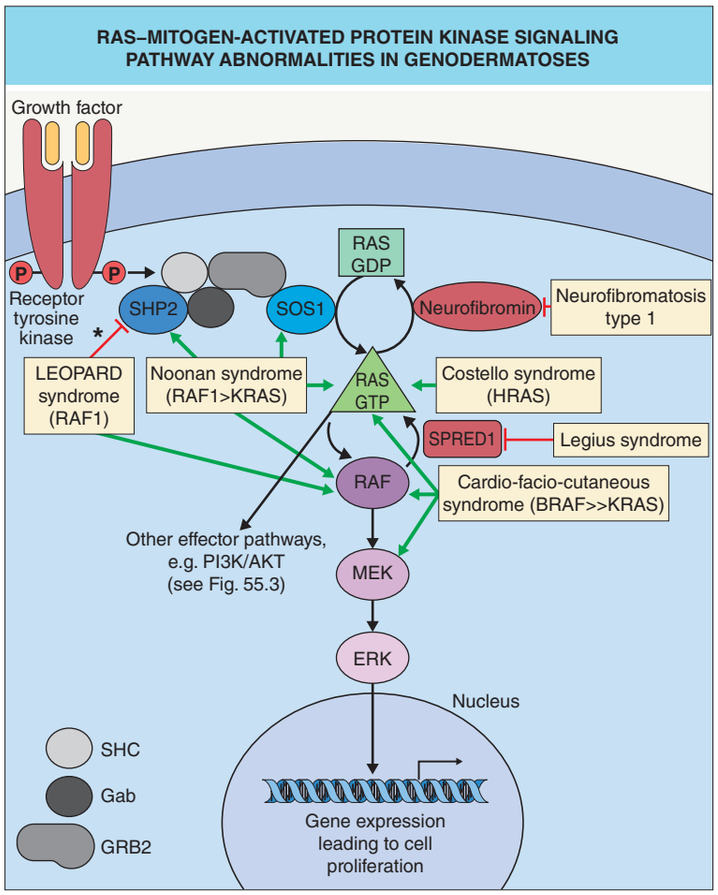

Fig. 55.4 RAS–mitogen-activated protein kinase (MAPK) signaling pathway abnormalities in genodermatoses. The phenotypic overlap among neurofibromatosis type 1 and Legius, Noonan, cardio-facio-cutaneous, Costello, and Noonan with multiple lentigines (also referred to as LEOPARD) syndromes is explained by underlying germline mutations in different components of the RAS–MAPK pathway that lead to activation of this signaling cascade. Of note, similar *somatic* activating mutations are found in a variety of benign and malignant tumors (e.g. *BRAF* or *NRAS* mutations in the majority of melanocytic nevi and melanomas; see Ch. 113) as well as epidermal/sebaceous nevi (see Ch. 62). Growth factor binding to receptor tyrosine kinases results in activated receptor complexes containing adapters such as Src *h*omology 2 domain-*c*ontaining (SHC), *g*rowth factor *r*eceptor-*b*ound 2 (GRB2), and GRB2-*a*ssociated *b*inding (Gab) proteins as well as SH2 domain-containing protein tyrosine phosphatase 2 (SHP2; encoded by *PTPN11*), which relays signals from activated receptors to RAS and deactivates negative regulators of RAS (e.g. Sprouty). The activated receptor complex recruits son of sevenless homolog 1 (SOS1), a guanine nucleotide exchange factor that increases levels of active RAS–guanosine triphosphate (GTP). In contrast, neurofibromin is a GTPase activating protein that promotes hydrolysis of RAS–GTP to RAS–guanosine diphosphate (GDP), which terminates signaling. **In vitro* studies suggest a dominant negative effect, but the consequences could vary depending on the substrate, cell type, or developmental stage.

Fig. 55.5 Costello syndrome due to a heterozygous activating *HRAS* mutation in a 3-year-old girl. **A** Verrucous periorificial (periocular, perinasal) plaques. **B** Loose acral skin with deep palmoplantar creases. Note the distal phalangeal transverse crease on the thumb. **C** Acanthosis nigricans.

of *a*denomatous *p*olyposis *c*oli) is due to mutations in the *APC* tumor suppressor gene that encodes an inhibitor of WNT/β-catenin signaling[33], and mutations in the APC downregulated 1 gene (*APCDD1*) underlie hereditary hypotrichosis simplex. Lastly, anonychia congenita and "palmoplantar keratoderma with cutaneous SCC and sex reversal" are caused by mutations in genes encoding R-spondins that activate WNT/β-catenin signaling.

CONTIGUOUS GENE SYNDROMES

Certain syndromic associations actually represent contiguous gene syndromes caused by large deletions that affect two or more neighboring genes. For example, deletions in the Xp22.3 region can give rise to X-linked recessive ichthyosis, X-linked recessive chondrodysplasia punctata, Kallmann syndrome (hypogonadotrophic hypogonadism with anosmia), ocular albinism type 1, short stature, and intellectual disability. Of note, more than 90% of patients with X-linked recessive ichthyosis have complete deletion of the *STS* gene and flanking sequences, which represents one of the highest incidences of chromosomal deletions among all genetic disorders. Additional genodermatoses that can present as contiguous gene syndromes include Ehlers–Danlos syndrome (due to tenascin-X deficiency) plus congenital adrenal hyperplasia (due to 21-hydroxylase deficiency), tricho-rhino-phalangeal syndrome plus multiple cartilaginous exostoses (together referred to as Langer–Giedion syndrome), and MIDAS (*mi*crophthalmia, *d*ermal *a*plasia, and *s*clerocornea) syndrome plus Aicardi syndrome (agenesis of the corpus callosum with a chorioretinal abnormality).

CUTANEOUS MOSAICISM

The current medical definition of a mosaic is: the coexistence of at least two genotypes in an individual derived from a single zygote, by the time

Downloaded for Anonymous User (n/a) at Egyptian Knowledge Bank from ClinicalKey.com by Elsevier on March 10, 2024. For personal use only. No other uses without permission. Copyright ©2024. Elsevier Inc. All rights reserved.

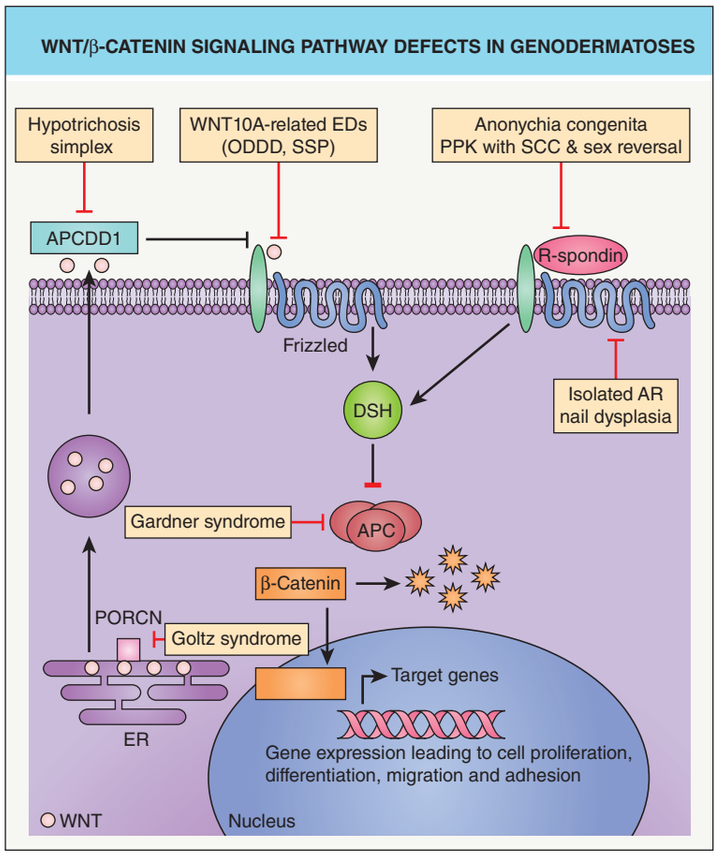

Fig. 55.6 WNT/β-catenin signaling pathway defects in genodermatoses. The porcupine homolog (PORCN) O-acyltransferase in the endoplasmic reticulum (ER) palmitoylates WNT proteins, facilitating their secretion. Extracellular WNT binds to the frizzled transmembrane receptor, which activates dishevelled (DSH), a cytosolic protein that inhibits the "destruction complex" (containing the adenomatous polyposis coli [APC] tumor suppressor protein) that mediates proteasomal degradation of β-catenin. As a result, β-catenin accumulates and is translocated to the nucleus, where it induces the transcription of genes that lead to cell proliferation, differentiation, migration, and adhesion. APC downregulated 1 (APCDD1) can inhibit WNT signaling. R-spondins are other secreted proteins that bind to frizzled and activate the WNT/β-catenin pathway. AR, autosomal recessive; EDs, ectodermal dysplasias; ODDD, odonto-onycho-dermal dysplasia; PPK, palmoplantar keratoderma; SCC, squamous cell carcinoma; SSP, Schöpf–Schulz–Passarge syndrome.

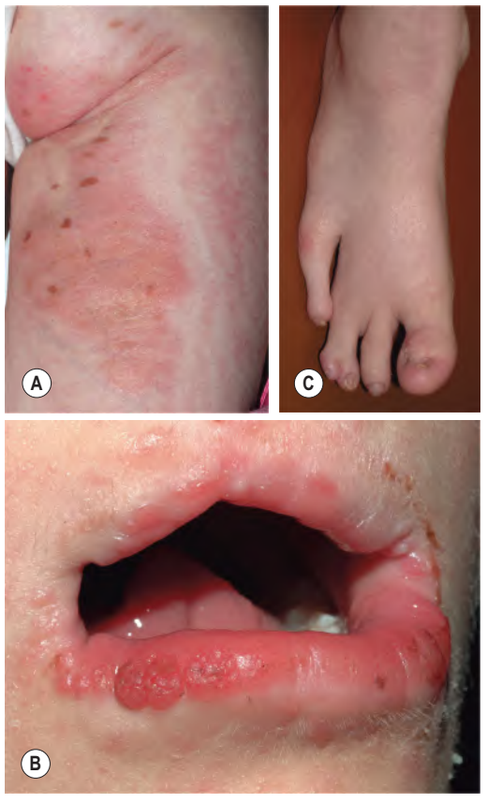

Fig. 55.7 Goltz syndrome (focal dermal hypoplasia). **A** Hyperpigmented macules and dermal atrophy with fat "herniation" on the posterior thigh. **B** Raspberry-like papillomas on the lower lip. **C** Ectrodactyly.

of birth, and which gives rise to a disease phenotype[34] (see Ch. 62). As a uniquely accessible organ, the skin provides an excellent opportunity to visualize and study mosaicism[35]. Patterns on the skin due to mosaicism include the lines of Blaschko, phylloid (see below), segmental with quadrilateral shapes, and non-segmental with circular shapes (see Fig. 62.1). Mosaicism for activating mutations affecting RAS-MAPK signaling or G protein α-subunits have been found to underlie a variety of birthmarks, including congenital melanocytic, epidermal, and sebaceous nevi as well as port-wine birthmarks and dermal melanocytosis. A single heterozygous mutation in a multipotent progenitor cell can lead to multiple types of birthmarks involving different skin lineages, such as nevus spilus (melanocytic) plus nevus sebaceus in phakomatosis pigmentokeratotica (*HRAS*) or port-wine birthmarks (vascular) plus dermal melanocytosis in phakomatosis pigmentovascularis (*GNAQ* or *GNA11*)[36,37]. Extracutaneous manifestations may occur if the mutation involves other organs such as the brain, eye, or bones.

Mosaic forms of autosomal dominant genodermatoses include: (1) a heterozygous postzygotic mutation occurring on a wild-type ("normal") background (type 1); and (2) a postzygotic "second hit" leading to loss-of-heterozygosity in the setting of a heterozygous constitutional mutation (type 2). The latter manifests clinically as a superimposed area of earlier onset or more severe disease than the background of generalized disease, e.g. linear porokeratosis in a patient with disseminated superficial actinic porokeratosis. Examples of type 1 mosaicism that have been confirmed on a molecular level include epidermolytic (*K1* or *K10*) and non-epidermolytic (fibroblast growth factor receptor 3 [*FGFR3*]) epidermal nevi; constitutional mutations in these genes produce epidermolytic ichthyosis and craniosynostosis syndromes associated with severe acanthosis nigricans (Fig. 55.8), respectively. Both type 1 and type 2 mosaicism have been documented for Darier disease (*ATP2A2*) and Hailey–Hailey disease (*ATP2C1*) (Fig. 55.9), while type 2 mosaicism has been confirmed for several genodermatoses due to a defective tumor suppressor gene, such as NF1, basal cell nevus syndrome (*PTCH1*), and PTEN hamartoma tumor syndrome.

All women and girls are *functional* mosaics due to the random, irreversible, stably inherited inactivation of one of the two X chromosomes that occurs in each cell during early embryonic development (lyonization). However, 15% of genes on the human X chromosome escape lyonization and 10% are variably inactivated. In women heterozygous for X-linked disorders, functional mosaicism can result in skin lesions that follow the lines of Blaschko or have other mosaic distribution patterns. This occurs in female patients with X-linked dominant, male-lethal disorders such as incontinentia pigmenti (*IKBKG/NEMO*), CHILD (*c*ongenital *h*emidysplasia with *i*chthyosiform nevus and *l*imb *d*efects) syndrome (*NSDHL*), Conradi–Hünermann–Happle syndrome (*EBP*), and Goltz syndrome (*PORCN*; see Fig. 55.7) as well as in female "carriers" of X-linked dermatoses such as hypohidrotic ectodermal dysplasia (*EDA*; Fig. 55.10) and *i*chthyosis *f*ollicularis–*a*trichia–*p*hotophobia (IFAP) syndrome (*MBTPS2*; Fig. 55.11). The gene encoding steroid sulfatase escapes lyonization, explaining why skin lesions in a mosaic pattern are not observed in female carriers of X-linked recessive ichthyosis.

REVERTANT MOSAICISM

Revertant mosaicism is a means of "natural gene therapy" in which a spontaneous secondary genetic phenomenon leads to rescue of a disease-causing mutation, allowing a mosaic clone of heterozygous cells to regain wild-type ("normal") function[38]. It has been described most often in patients with EB (see Ch. 32), potentially explaining the tendency of some forms of this condition to improve with age. A growth advantage and selective pressures (e.g. blistering) may help to increase the number of revertant cells over time. Revertant mosaicism via mitotic recombination accounts for the numerous small "islands" of normal skin in a

Downloaded for Anonymous User (n/a) at Egyptian Knowledge Bank from ClinicalKey.com by Elsevier on March 10, 2024. For personal use only. No other uses without permission. Copyright ©2024. Elsevier Inc. All rights reserved.

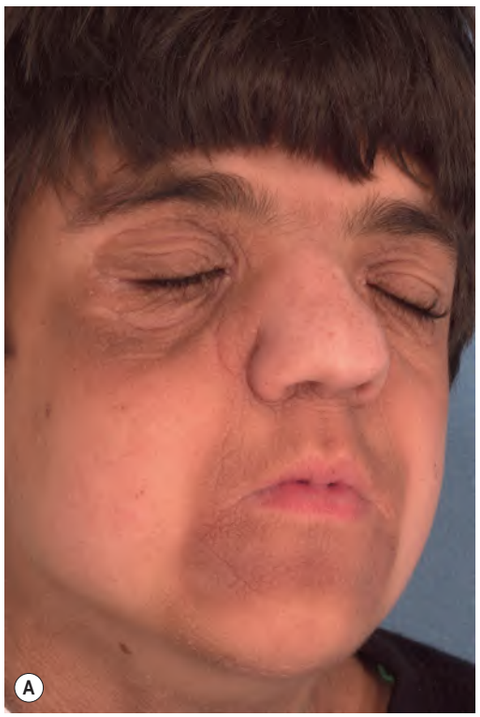

Fig. 55.8 Skin disease due to fibroblast growth factor receptor 3 (FGFR3) defects. A Severe acanthosis nigricans in a patient with the Crouzon craniosynostosis syndrome. **B** Systematized epidermal nevus in a young boy who had developmental delay. These conditions can be caused by germline and mosaic *FGFR3* mutations, respectively. *A, Courtesy Seth J. Orlow, MD, PhD.*



Fig. 55.9 Type 2 segmental Hailey–Hailey disease. This 7-year-old girl had a history of recurrent blistering on the right abdomen, groin, and thigh since infancy.

background of ichthyosiform erythroderma that characterize ichthyosis en confetti[39]. Affected individuals have specific frameshift mutations in *KRT10* or *KRT1*, which produce mutant proteins with an arginine-rich C-terminus that redirects them to the nucleolus; this mislocalization may have a role in promoting the reversion.

CHROMOSOMAL DISORDERS

Chromosomal disorders represent abnormalities in the number or structure of chromosomes. Aneuploidy refers to having an additional or missing chromosome; examples that are compatible with postnatal survival include complete trisomies for chromosomes 21 (Down syndrome; Fig. 55.12), 18 (Edwards syndrome), and 13 (Patau syndrome) as well as monosomy for the X chromosome (Turner syndrome) and XXY (Klinefelter syndrome) or XYY karyotypes. Mosaic aneuploidies or partial trisomies and monosomies due to duplications, deletions, or translocations of portions of chromosomes can also occur. The cutaneous and extracutaneous features of several relatively common chromosomal disorders are presented in Table 55.6.

Phylloid hypomelanosis, characterized by leaf-like hypopigmented patches (Fig. 55.13), usually results from mosaic trisomy 13. In contrast, hypo- or hypermelanotic streaks and swirls that follow the lines of Blaschko, occasionally with associated extracutaneous findings, can be caused by mosaicism for a variety of chromosomal aberrations (see Ch. 62).

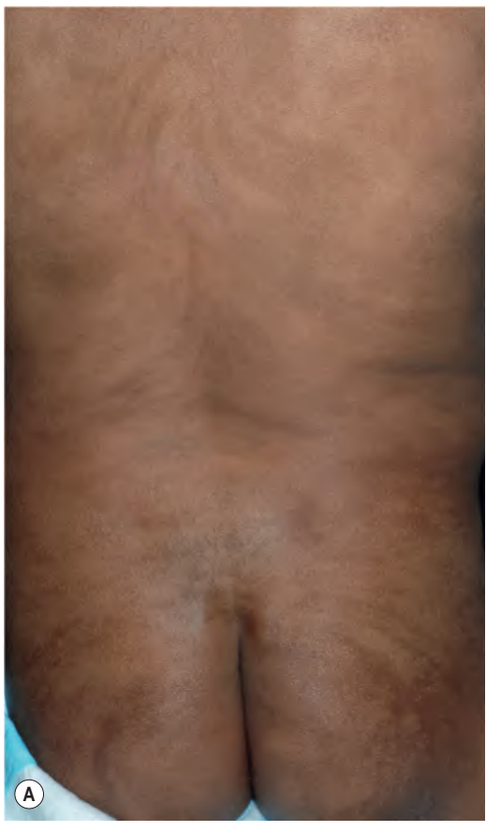

Fig. 55.10 Female "carriers" of X-linked hypohidrotic ectodermal dysplasia. A The skin within hyperpigmented streaks and swirls following the lines of Blaschko is slightly depressed and very smooth, in contrast to follicular prominence in the surrounding areas. Starch-iodine testing on the back disclosed a patchy distribution of active sweat glands. This 2-year-old girl also had whorled areas of sparse hair on the posterior scalp and several cone-shaped teeth. **B** A color thermogram demonstrates an asymmetric distribution of skin temperature on the anterior trunk. *B, From Clark RP, Goff MR, MacDermot KD. Identification of functioning sweat pores and visualization of skin temperature patterns in X-linked hypohidrotic ectodermal dysplasia by whole body thermography. Hum Genet 1990;86:7–13.*

Downloaded for Anonymous User (n/a) at Egyptian Knowledge Bank from ClinicalKey.com by Elsevier on March 10, 2024. For personal use only. No other uses without permission. Copyright ©2024. Elsevier Inc. All rights reserved.

Fig. 55.11 Ichthyosis follicularis with atrichia and photophobia (IFAP) syndrome. Note the confluent psoriasiform plaques on the scalp.

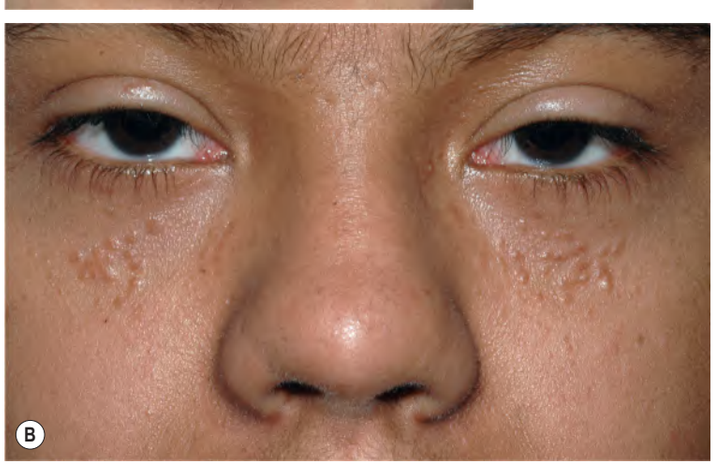

Fig. 55.12 Cutaneous manifestations of Down syndrome (trisomy 21). A Full lips with cheilitis and a protruding, fissured tongue. **B** Multiple facial syringomas.

INSIGHT INTO ACQUIRED SKIN DISORDERS PROVIDED BY THE STUDY OF GENODERMATOSES

Inherited monogenic skin disorders can serve as models to improve our understanding of the pathogenesis of more common acquired skin diseases. For example, basement membrane proteins that are defective in JEB (e.g. type XVII collagen [bullous pemphigoid antigen 2], laminin 332 subunits) and dystrophic EB (type VII collagen) are also targeted in autoimmune blistering diseases such as bullous pemphigoid, mucous membrane (cicatricial) pemphigoid, and EB acquisita (see Fig. 28.7). The excessive granulation tissue that develops due to a truncated laminin α3 subunit in patients with laryngo-onycho-cutaneous syndrome has also provided clues to the role of this protein in regulating angiogenesis and granulation tissue formation during normal wound healing. Likewise, observation of similar dermal hyalinization in lichen sclerosus and the rare genodermatosis lipoid proteinosis led to the discovery of autoantibodies against extracellular matrix protein 1, the protein that is defective in the latter disorder, in the majority of patients with lichen sclerosus[40]. In addition, investigation of monogenic type I interferonopathies such as Aicardi–Goutières syndrome, familial chilblain lupus, and STING-associated vasculopathy with onset in infancy (SAVI; see Ch. 45) that are caused by abnormal processing of and immune responses to nucleic acids has provided pathogenic insights and potential targeted therapeutic approaches for lupus erythematosus and dermatomyositis[41,42].

Loss-of-function variants in the gene that encodes filaggrin, the protein that aggregates keratin filaments during keratinocyte terminal differentiation (see Ch. 56), not only cause ichthyosis vulgaris but also represent a major predisposing factor for atopic dermatitis, with a significantly higher prevalence (20%–50%) in individuals with atopic dermatitis compared to the general population (<5%–10%). Defective filaggrin also represents a predisposing factor for asthma, but specifically that occurring in individuals with pre-existing atopic dermatitis. Barrier dysfunction due to abnormalities in the serine protease inhibitor (SPINK5) involved in Netherton syndrome may also play a role in the pathogenesis of atopic dermatitis, and polymorphisms in *SPINK5* have been shown to be associated with this common acquired skin disease.

PRENATAL AND PREIMPLANTATION GENETIC DIAGNOSIS

In the past, prenatal diagnosis was based on techniques such as ultrastructural and immunohistochemical analysis of fetal skin biopsy specimens obtained between 18 and 22 weeks' gestational age (GA). Today, such methods have been largely replaced by DNA-based testing that is less invasive and more reliable. The diagnosis of genodermatoses for which the molecular basis is known can be established prenatally by performing chorionic villus sampling (at 10–12 weeks' GA) or amniocentesis (at 14–16 weeks' GA) and analyzing fetal DNA (after determining the underlying genetic defect in family members)[43]. Non-invasive prenatal diagnostic techniques that utilize fetal cells or cell-free DNA in the maternal circulation have also been developed[44,45]. Preimplantation genetic diagnosis is another option for severe genetic skin diseases. This involves analysis of DNA from single cells (blastomeres) extracted from late cleavage stage embryos following *in vitro* fertilization[46]. In this way, knowing the genetic bases of heritable skin conditions may be of tremendous value to affected families.

TREATMENT FOR HEREDITARY SKIN DISORDERS

Gene Therapy

The accessibility of the skin makes it an excellent target for gene therapy. In recent years, particular progress has been made in developing approaches to gene therapy for EB. For example, *ex vivo* gene therapy has led to functional correction of the skin fragility phenotype in patients with JEB due to *LAMB3* mutations and dystrophic EB due to *COL7A1* mutations, demonstrating for the first time successful

Downloaded for Anonymous User (n/a) at Egyptian Knowledge Bank from ClinicalKey.com by Elsevier on March 10, 2024. For personal use only. No other uses without permission. Copyright ©2024. Elsevier Inc. All rights reserved.

SKIN FINDINGS ASSOCIATED WITH CHROMOSOMAL ABERRATIONS				
Disorder	**Chromosomal aberration**	**Mucocutaneous anomalies**	**Extracutaneous anomalies**	**Comments**
Turner syndrome	45, XO	Congenital lymphedema (usually resolves by age 2 years), low posterior hairline, numerous melanocytic nevi, small hyper-convex nails, tendency to form keloids	Short stature, webbed neck, "shield-like" chest with widely spaced nipples, absence of sexual development, cardiovascular defects, renal malformations, sensorineural hearing loss, autoimmune hypothyroidism	Mosaicism (e.g. 45, XO/46, XX or 45, XO/46, XY) in ~40% of patients
Klinefelter syndrome	47, XXY	Varicose veins, leg ulcers	Tall stature, gynecomastia, small testes, infertility	Mosaicism 46, XY/47, XXY in ~20% of patients; uncommon variants include 48, XXXY and 48, XXYY
Trisomy 21 (Down syndrome)	47, XY, +21 47, XX, +21	Single palmar crease, protruding scrotal tongue, cheilitis (see Fig. 55.12A), multiple syringomas (often with calcification; see Fig. 55.12B), alopecia areata, ichthyosiform hyperkeratosis, keratosis pilaris, milia-like calcinosis cutis, elastosis perforans serpiginosa, multiple collagenomas, cutis marmorata/acrocyanosis; a predisposition to developing folliculitis, dermatophyte infections and Norwegian scabies; vesiculo-pustular eruptions associated with neonatal transient myeloproliferative disorder	Brachycephaly, characteristic facial appearance (e.g. epicanthal folds, flat nasal bridge), Brushfield spots (speckled irides), broad hands, brachydactyly, atlantoaxial instability, mental disability, immunodeficiency, congenital heart defects, duodenal atresia, leukemia (especially acute myeloid leukemia), hearing loss, autoimmune hypothyroidism	
Phylloid hypomelanosis (see Fig. 55.13)	Mosaic trisomy 13	Round, oval, or oblong hypopigmented macules resembling floral ornaments	Absence of corpus callosum, retinal coloboma, craniofacial defects, brachy-dactyly, clinodactyly, camptodactyly, conductive hearing loss	
Pallister–Killian syndrome	Mosaic tetrasomy 12p (isochro-mosome 12p)	Hypopigmented and/or hyperpigmented streaks; fine, sparse hair during infancy	Postnatal growth deficiency, characteristic facies (anteverted nostrils, down-turned mouth with thin upper lip), mental disability	

Table 55.6 Skin findings associated with chromosomal aberrations.

Fig. 55.13 Phylloid hypomelanosis due to mosaic trisomy 13. This condition is characterized by leaf-like and oblong patches of hypopigmentation in a pattern reminiscent of a floral ornament. *Courtesy Arne König, MD and Rudolf Happle, MD.*

gene therapy for a disease of solid tissue[47]. The technique involves retroviral-mediated transduction of autologous epidermal cells with a wild-type copy of the *LAMB3* or *COL71A* gene, followed by grafting of epidermal sheets grown from the genetically corrected cells. *In vivo* topical gene therapy with beremagene geperpavec (B-VEC), a non-replicating *COL7A1*-containing herpes simplex virus type 1 vector, was recently FDA-approved as a treatment to promote wound healing in patients with dystrophic EB[48]. Gene editing using technologies such as CRISPR-Cas9 and base editing to restore expression of functional proteins in EB is also under investigation[49] (see Fig. 3.13). Additional strategies include the use of drugs such as aminoglycoside antibiotics (e.g. topical or intravenous gentamicin) to induce read-through of nonsense mutations in recessive forms of EB as well as utilization of small interfering RNA to specifically "knock down" expression of the mutant protein in dominant-negative disorders such as EB simplex and pachyonychia congenita.

Therapy Targeting Affected Molecular Pathways

Understanding the molecular pathway that is affected in genodermatoses can translate into effective therapy. For example, loss-of-function mutations in tumor suppressor genes that negatively regulate the growth-promoting mTOR (*m*echanistic *t*arget *o*f *r*apamycin) signaling pathway underlie several hamartoma syndromes, including tuberous sclerosis complex, the PTEN hamartoma tumor syndrome, and Peutz–Jeghers syndrome (see Fig. 55.3). Recognition of the mTOR overactivation common to these disorders has led to successful treatment of affected individuals with the mTOR inhibitors sirolimus (rapamycin) and everolimus. For example, use of these agents in patients with tuberous sclerosis complex has resulted in regression of subependymal giant cell astrocytomas, renal angiomyolipomas, pulmonary lymphangioleiomyomatosis and (with topical as well as oral therapy) facial angiofibromas[50]. Additional examples of molecular advances resulting in successful targeted therapy include the use of the MEK inhibitor selumetinib for NF1-associated plexiform neurofibromas, the PI3K inhibitor alpelisib for the PIK3CA-related overgrowth spectrum, and the AKT inhibitor miransertib for Proteus syndrome[51,52].

Downloaded for Anonymous User (n/a) at Egyptian Knowledge Bank from ClinicalKey.com by Elsevier on March 10, 2024. For personal use only. No other uses without permission. Copyright ©2024. Elsevier Inc. All rights reserved.